



Research Article

Minimally Invasive Reconstruction of Atrophic Maxilla Using Novel TTPHIL Technique - A Retrospective Evaluation of Pterygoid Implants and Prosthesis Success in 75 Patients

Venkat P. Ratna Nag¹, Michael Levit², Sarika Puppala¹, Smitha Daniel¹, Tejashree Bhagwatkar¹, Leah Levit³, Leon Ardekian^{4*}

¹Institute for dental Implantology, Hyderabad, India

²Department of Prosthodontics, Hadassah Medical Organization and Faculty of Dental Medicine, Hebrew University of Jerusalem, Jerusalem, Israel

³Research Fund of the Hadassah Medical Organization, Jerusalem, Israel

⁴Suheir Professionals, Oral and Maxillofacial Surgery and Implantology Center, Migdal Haemek, Israel

*Corresponding author: Leon Ardekian, Suheir Professionals, Oral and Maxillofacial Surgery and Implantology Center, Migdal Haemek, Israel

Citation: Nag VPR, Michael L, Sarika P, Daniel S, Bhagwatkar T, et al. (2022) Minimally Invasive Reconstruction of Atrophic Maxilla Using Novel TTPHIL Technique - A Retrospective Evaluation of Pterygoid Implants and Prosthesis Success in 75 Patients. Dent Adv Res 7: 186. DOI: 10.29011/2574-7347.100086

Received Date: 13 January, 2021; **Accepted Date:** 18 January, 2021; **Published Date:** 20 January, 2021

Abstract

Aim: Implant reconstruction of posterior atrophic maxilla is a very challenging procedure for both general dentists and maxillofacial surgeons. Many surgical techniques have been described for the reconstruction of the posterior maxilla, including extensive surgical approaches. The objective of the current study is to evaluate the cumulative success rates of pterygoid implants and their prostheses, placed by the novel minimally invasive TTPHIL[®] (Tall Tilted Pin Hole Placement with Immediate Loading) technique.

Methods: A retrospective observational study was performed on patients who were rehabilitated with pterygoid implants between the years 2013 and 2016, with a follow up period of at least two years after implant loading. During TTPHIL - ALL TILT[®] protocol, tall tilted implants were placed at the pterygoid region in a flapless manner, utilizing the bi-cortical engagement. In the current study, two outcome variables were considered: 1. Implant success, 2. Prosthesis success. The predictor variables were: 1. Age, 2. Gender, 3. Implant length, 4. Implant width, 5. Angle of placement, 6. Bone type. Fisher's exact test was implemented in order to compare the overall implant and prosthetic success, with respect to clinical and demographic variables. The relation between predictor variables to outcome variables was also examined.

Results: The study included a total of 125 pterygoid implants placed in 75 patients. The 2-year overall pterygoid implant success rate was 96.8%. Prosthesis success was 99.2%. Mean bone loss around pterygoid implants after two years of loading was 0.28 mm (range 0.17-0.39 mm). None of the examined predictor variables were found to have any significant effect on either implant or prosthesis success.

Conclusions: Placement of pterygoid implants, using the TTPHIL technique, leads to little bone loss and to similar or higher success rate in comparison to conventional techniques of pterygoid implant placement. Prosthesis stability is also attained when using this novel method. Therefore, TTPHIL technique should be considered as a minimally invasive alternative for rehabilitation of atrophic maxilla with pterygoid implants, particularly during COVID-19 pandemic owing to a few number of required appointments and short period to final rehabilitation.

Keywords: Accessibility of Care; Atrophic Maxilla; Bicortical Engagement; COVID-19; Edentulism; Flapless Surgery; Immediate Loading; Oral Rehabilitation; Pterygoid Implants; TTPHIL Technique

List of abbreviations

AASA	:	American Society of Anesthesiologists
CAD-CAM	:	Computer Aided Design – Computer Aided Manufacturing
CBCT	:	Cone Beam Computed Tomography
COVID-19	:	COronaVirus Disease 2019
DMLS	:	Direct Metal Laser Sintering
HD	:	High Definition
Ncm	:	Newton centimeter
TTPHIL loaded	:	Tall, Tilted, Pin Hole, Immediately loaded
STL	:	Stereolithography

Introduction

Since the introduction of osseointegration concept by Brånemark et al., dental implants have been a successful treatment modality for reconstruction of edentulous patients [1]. Nonetheless, the edentulous posterior maxilla poses numerous limitations when placing conventional dental implants. The main limiting factors are related to poor bone quality and to inadequate bone quantity, which are even more reduced by pneumatization of the maxillary sinus [2]. Other anatomical challenges are large fatty marrow spaces, rare presence of cortical bone and restricted access to the atrophic maxilla [3-4]. These factors may impair primary stability and, consequently, reduce success and survival of implants and prosthesis [5].

Numerous surgical techniques of posterior maxilla reconstruction have been described, including the alveolar distraction, sinus floor augmentation, guided bone regeneration, zygomatic implants and the use of pterygoid, pterygomaxillary or pterygotuberosity implants [6-8]. The most common technique is sinus floor augmentation, which has gained popularity since its introduction [9]. However, during the last decade this technique has lost its popularity due to many drawbacks, such as complex and traumatic manipulation of the patient, sinusitis, sinus membrane perforation, bone graft infection and delayed loading [10,11]. An alternative method to sinus floor augmentation is the use of multiple short and wide implants, which have a greater surface area and provide adequate stability to implants and prosthesis [12]. These traditional techniques have longer posterior cantilevers in their prosthetic design, which might result in complications, such as marginal bone

loss, screw and prosthesis fracture and even loss of implant osseointegration [13-14].

In 1989, Tulasne has first introduced the placement of implants in the pterygoid region for the rehabilitation of the atrophic posterior maxilla [15]. In the literature, pterygoid implants are also designated as pterygomaxillary implants or pterygotuberosity implants. These implants are placed at an angulation of 25° to 45° in relation to the maxillary plane and engage the maxillary tuberosity, the pyramidal process of the palatine bone and, finally, the pterygoid process of the sphenoid bone [16]. The apical part of these implants is placed in a pillar of the compact tuberopalatopterygoid bone column, where it osseointegrates easily. The distal location of the pterygoid implants in the maxillary arch provides support and stability for a bone-anchored prosthesis, and eliminates the need for bone grafting procedures or posterior prosthetic cantilevers [15].

The TTPHIL™ (Tall and Tilted Pin Hole Immediately Loaded implants) concept has evolved from various ideologies in implantology: basal, pterygoid and angulated implants under immediate loading [16-19]. To maximize the success of rehabilitation, the TTPHIL™ technique utilizes long, tilted, bicortical implants in anterior and posterior maxilla and mandible. Tall (18mm-25mm) and tilted (25°-45°) pterygoid implants are placed in the posterior maxilla. Longer implants osseointegrate more easily, as they provide more surface area by utilizing bicortical anchorage. The implants are placed in a pinhole manner, i.e. flapless. In most cases good primary stability is achieved, which allows immediate loading with permanent prosthesis within 48 hours after implant placement. In the minority of cases, loading is delayed for three months, which is required for the remodeling of bone around the implants for appropriate osseointegration [16-18]. The aim of this study was to evaluate the success rates of pterygoid implants and the prostheses placed by TTPHIL method, with correlation to various clinical and demographic variables.

Materials and Methods

Study Design

A retrospective analysis was performed on 75 patients (60 partially edentulous and 15 completely edentulous) who had undergone TTPHIL pterygoid implant surgery and implant rehabilitation between 2013 to 2016. Data was collected from these patients in a chronological order. The patients' personal data, general health and dental status, diagnoses and treatment plan were recorded in manual case sheets. In addition, a digital folder of each patient included preoperative and follow-up panoramic radiographs, clinical photographs and software surgery design. Each follow-up visit was recorded in a separate folder for each patient, and included an updated panoramic radiograph, software bone-loss analysis and implant status (success/failure). The data was secured and access was available only to the dental care team. All patients underwent

the same surgical, prosthetic and a two-year follow-up protocol after the pterygoid implant placement. Patients were given access to the study plans and findings, which encouraged their positive attitude towards further follow-ups. Ethical approval was not applicable for this study, due to the retrospective nature of data analysis.

Pterygoid Implant Surgical Protocol Using TTPHIL® Technique

Patient consent was obtained prior to surgical procedure. All patients have self-volunteered to participate in the study analysis. A Cone Beam Computed Tomography (CBCT) was performed in each case. The dicom image files were converted to STL files, on which the surgical planning was done using specific software (BlueSkyPlan, United States). Vital anatomic structures, such as sinus walls and pterygoid venous plexus, were identified and excluded from the planned operative field. Local anesthesia with 2% lidocaine hydrochloride and adrenaline (1:200000) was given. In a flapless approach, TTPHIL mucosa supported surgical guide was placed intraorally above the alveolar ridge (In2Guide, Cybermed Inc., USA). In partial edentulous cases, teeth supported guide was used (Figure 1).

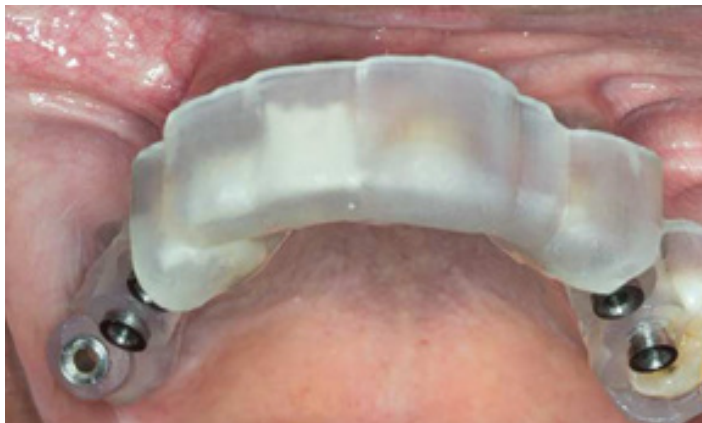

Figure 1: Teeth supported surgical guide is placed over the remaining teeth and the maxillary ridges and its stability is examined. In totally edentulous cases, mucosa supported guide was used.

The drilling was initiated using a pilot drill with a contra-angled hand piece (20:1) over the crest of the maxillary tuberosity, in the site previously occupied by interdental space between 1st and 2nd molars. Penetration through the cancellous bone was done. The drill was directed towards the tuberopalatopterygoid column until resistance was felt from the high-density pterygoid process. Just after crossing the whole width of the pterygoid process, the pilot drilling stopped. The implant bed preparation continued, using a 2.2 mm pterygoid drill. No wider drill was used (Figure 2a). The implant bed was left under-widened, in order to enable placement of implants with higher torque and stability. Pterygoid implants (Bioline-i-spiral, Bioline dental implants, Frankfurt, Germany)

were diagonally inserted in a superior, posterior and distal direction, towards the pterygopalatine fossa of the sphenoid bone (Figure 2b). In relation to the sagittal plane, the distal angulation of the pterygoid implants varied between 25 degrees to 45 degrees. This angle size was determined by tuberosity height and maxillary sinus floor. The pterygoid implant insertion was initiated by low-speed handpiece. Due to increasing resistance of the under-prepared implant bed the low speed rotation stopped and the implant insertion continued manually by a ratchet torque wrench. The implants were placed subcrestally. Primary stability was verified if torque of 70 Ncm was achieved (Figure 2c). Reverse torque test was performed at torque ≥ 45 N/cm (Figure 2d).

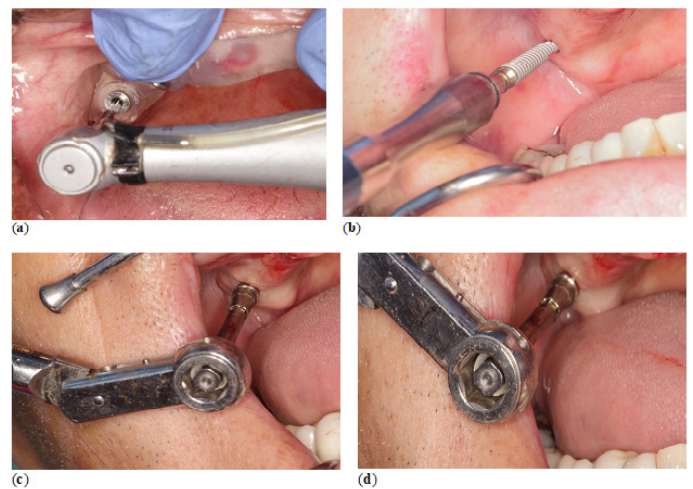


Figure 2: Intraoperative photographs. (a) Implant bed preparation with sole 2.2 mm drill through the surgical guide. No wider drill was used; (b) Insertion of the pterygoid implant. Note the angulation to superior, distal and posterior directions; (c) Assurance of gaining primary stability at torque of 70 N/cm; (d) Passed reverse torque test at 45 N/cm.

The dimensions of the pterygoid implants were selected according to the bone type and achievement of primary stability. Implant length was 18 mm, 20 mm, 22 mm or 25 mm, and implant width was 3.75 mm or 4.2 mm. Multiunit abutments were then fitted with torque of 30 Ncm (Angulated multiunit abutment, Bioline dental implants, Frankfurt, Germany). The angulation range of multiunits was 8° to 40° with collar height of was 2 or 3 mm. The multiunits were fitted in order to compensate for the implant's angulation. Parallelism was obtained on the same day of surgery.

Two step multiunit level open tray impressions were made with transfer copings for multiunits. Jaw relations were recorded at rest position and at the desired intercuspal closure. Screw retained temporary acrylic prosthesis was provided immediately thereafter, by luting with acrylic (Unifasttrad, GC America) the multiunit titanium sleeves to already existing preoperatively planned

and prepared temporary prosthesis by CAD-CAM. Postoperative panoramic radiographs (VatechPaX-i, Hwaseong-si, Gyeonggi-do, South Korea) were done in order to confirm the position of the pterygoid implants along with the fitted multiunits.

Cobalt chromium framework was printed by direct metal laser sintering (DMLS) and checked intraorally. Secondary bite was registered, teeth shade selected using Vita shade guide (Vita Zahnfabrik, Bad Sackingen, GmbH, Germany). Ceramic bisque layering was done and examined intraorally. Final occlusion adjustment was done and the bridge was sent for glazing. The patient was then rehabilitated with permanent screw retained porcelain to metal fixed prosthesis. The prosthetic screws were tightened with 30N/cm torque. After prosthesis placement, panoramic radiograph was done (Figures 3-4). The patients were advised to adhere to meticulous oral hygiene maintenance, hygienists visits and annual follow up. The full technique protocol was described in details by Nag PVR, et al. [19].

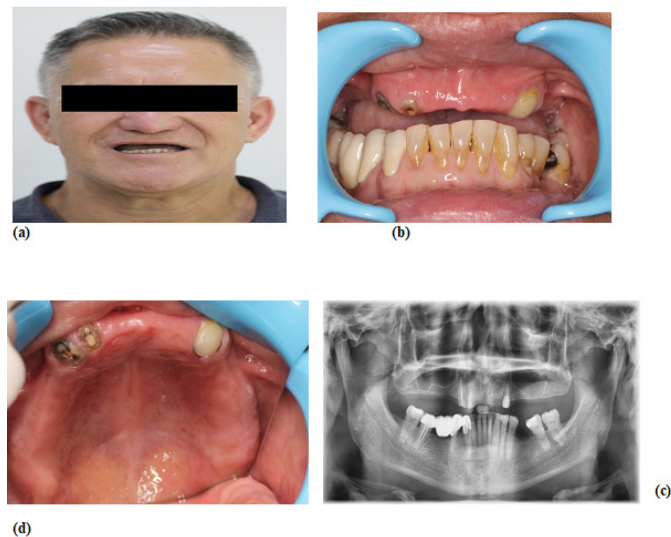

Figure 3. Pre-operative clinical photographs and panoramic radiograph of a full arch rehabilitation case: (a) Patient's smile; (b) Intraoral view of the maxillary buccal aspects; (c) Intraoral view of the maxillary palatal aspects; (d) panoramic radiograph.

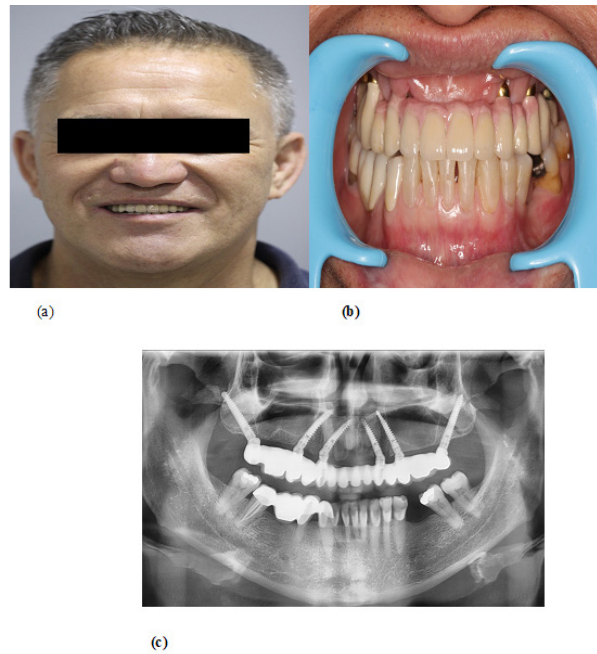


Figure 4: Post-operative clinical photographs and a radiograph. (a) Patient's smile; (b) Intraoral view of the maxillary buccal aspects; (c) Panoramic radiograph. Note the engagement of both of the pterygoid implants into the pterygoid plates.

Patients Selection

Inclusion criteria: 1. Good general health. 2. No contraindications for surgery. 3. Posterior atrophic maxilla. 4. Planned for at least one pterygoid implant. 5. Radiographic bone width of at least 6 mm at the future pterygoid implant bed. 6. No signs and symptoms of sinusitis. 7. without sinus floor augmentation in the past or any other bone graft procedure in the maxilla. 8. A minimum follow-up of 2 years after implant placement.

Exclusion criteria: 1. Medically compromised patients, with ASAII grade or more. 2. Patients receiving or have received bisphosphonates for any reason. 3. Patients with acute or active disease. 4. No achievement of implant primary stability at 70 N/cm at the moment of surgery. 5. Failed reverse torque test at ≥ 45 N/cm during surgery. 5. Patients who received pterygoid implants

but no prosthetic rehabilitation. 6. Patients who are uncooperative with routine dental hygiene and professional dental prophylaxis.

Study Variables - Outcome Variables

Implant success. According to Albrektsson et al., the criteria for success of any pterygoid implant were based on both clinical and radiographic examinations [20]. Clinical findings included absence of mucositis, discomfort, pain, bleeding or any exudate. Clinical mobility was examined by individual stability testing as described by Ross et al. at the moment of final prostheses delivery [21]. The pterygoid implant multiunit was tried to be lightly tightened by torque ratchet without simultaneously counteracting of the force by clamping the multiunit. Any mobility or sensation of pain from the anchorage unit was considered as a sign of lost osseointegration. Radiographic success was considered if each implant revealed not more than 1.0 mm of marginal bone resorption during the first year of loading, followed by bone loss not greater than 0.2 mm annually after the first year of function, as well as absence of any peri-implant pathoses or radiolucencies. The total follow up time for each implant was calculated from the date of implant placement to the date of last follow up visit.

Prosthetic success. The prostheses were evaluated objectively and subjectively by criteria of comfort, stability and function. A prosthesis was considered a failure if it needed to be replaced by an alternative prosthesis. Total survival time for each prosthesis was calculated from the date of delivery to the date of the last follow-up visit for each patient.

Predictor variables: Age, gender, implant length, implant width, implant placement angulation and bone type.

Bone Loss Evaluation

The pterygoid implants were radiographically evaluated at three consequential time-points: immediately after loading (few days after surgery); 1st follow-up (1 year after prosthesis delivery); 2nd follow-up (2 years after prosthesis delivery). OPG were standardized in a pilot exam consisting of 12 cases by two independent examiners in order to rule out inter-examiner and intra-examiner bias. The examiners were asked to measure the radiographic distance between the Anterior Nasal Spine (ANS) to posterior wall of sinus preoperatively and postoperatively in each of the 12 cases. By setting the same parameters: Midsagittal line, Canine laser beam and Frankfurt-Horizontal plane with exposure time of 13.5 sec (HD), further standardization was achieved. A line was traced between two fixed reference points for calculation of marginal bone loss: point A - implant-prosthetic restoration junction; point B - the bone crest. Each side of the pterygoid implant was assessed: the mesial and the distal. The annual differences in the length of this line were interpreted as marginal bone loss, which has occurred between the follow-ups.

Data Collection

The following parameters were retrospectively studied from demographic patient records, in addition to basic patient data: 1. Drop out. 2. Implant failure. 3. Prosthetic failure. 4. Amount of marginal bone loss mesial and distal to each pterygoid implant. The bone loss was recorded for each patient one year and two years after prosthesis delivery. For each case, panoramic radiographs were taken annually for evaluation of bone loss, implant and prosthesis success.

Statistical Analysis

The analysis was performed using the statistical analysis software: SPSS for Windows, version 18 (IBM, USA). P-value of <0.05 was considered statistically significant. Fisher’s exact test was performed in order to compare the overall implant and prosthetic success with respect to different clinical and demographic variables. The statistical methodology and study results were reviewed by an independent statistician.

Results

The study was comprised of 75 healthy patients (23 females and 52 males) with severely resorbed edentulous posterior maxilla with an age range between 30 to 82 years, when mean age was 57 years. No drop out of patients was recorded. Of the 125 pterygoid implants, 121 implants were considered as a success during the cumulative 2-year follow up period. Four implants failed within the first two months after surgery and were accompanied by patient’s complaints on pain, prosthetic mobility, bleeding or discomfort. The failures were confirmed by failed clinical mobility testing [21]. After two months, no failures were noted. The 2-year overall pterygoid implant and prosthesis survival rate was 96.8%. All study variables are summarized in table 1.

Variable	Category	Mean ± SD/N(%)
Age		57±9.73
Gender	Male	89 (71.2)
	Female	36 (28.8)
Implant length (mm)	18	17 (13.6)
	20	70 (56.0)
	22	22 (17.6)
	25	16 (12.8)
Implant width (mm)	3.75	60 (48.0)
	4.2	65 (52.0)
Angle of placement	25	34 (27.2)
	35	37 (29.2)
	45	54 (43.2)
Bone type	3	103 (82.4)
	4	22 (17.6)

Table 1: Demographic and clinical characteristics of the pterygoid implant patients.

The mean bone loss around pterygoid implants after 2 years of loading was 0.28 mm (mesially - 0.29 mm, distally - 0.26 mm) (Table 2). All implants were placed in type 3 or 4 bone. Of 125 pterygoid implants, 103 were placed in type 3 bone and three implants failed to osseointegrate. The remaining 22 implants were placed in type 4 bone and only one of these implants failed to osseointegrate. Out of 75 patients, one patient had chipping of ceramic supported by a pterygoid implant, which was replaced by new prosthesis (Table 3). The overall implant and prosthesis survival after two years of follow up are presented in table 4.

Follow-up period	Side	Mean (Std)	Range (Min-Max)
1-year	Mesial	0.27 (0.05)	0.15 – 0.36
	Distal	0.24 (0.05)	0.12 – 0.31
	Average	0.25 (0.05)	0.14 – 0.34
2-years	Mesial	0.30 (0.05)	0.19 – 0.39
	Distal	0.27 (0.06)	0.14 – 0.37
	Average	0.28 (0.05)	0.17 – 0.38

Table 2: Marginal bone loss (in mm) of 121 pterygoid implants over 2 years of follow-up.

Follow-up period	Status	N(%)
1 year implant	Survival	121 (96.8)
	Failure	4 (3.2%)
1 year prosthesis	Survival	124 (99.2)
	Failure	1 (0.8)
2 years implant and prosthesis	Survival	121 (96.8)
	Failure	4 (3.2)

Table 3. Survival vs. failure of pterygoid implants and related prostheses over 2 years of follow-up.

Variable	Category	2 years survival (%)	P value
Age	≤50	100	0.474
	>50	96.2	
Gender	Male	96.6	0.674
	Female	97.2	

Implant length (mm)	18	94.1	0.251
	20	98.6	
	22	90.6	
	25	100	
Implant width (mm)	3.75	98.3	0.34
	4.2	95.4	
Angle of placement	25	94.1	0.358
	35	100	
	45	96.3	
Bone type	3	97.1	0.544
	4	95.5	

Table 4: Overall survival of pterygoid implants and prostheses after 2 years of service according to demographic and clinical parameters.

Discussion

The aim of the present study was to evaluate the success rates of pterygoid implants and their permanent rehabilitation, using the novel minimally invasive TTPHIL technique. The empirical evidence on the success of this novel method has to be compared to the already known data on pterygoid implants. However, the documented evidence on the success of the conventional pterygoid implant surgery has been only moderately covered by the literature [22].

Balshi et al. reported 3 clinical series of pterygoid implants [23-25]. In 1995 they made a preliminary study in which 51 pterygoid implants with machined surfaces were placed in 41 patients, with a follow-up period of 1–63 months. The success rate was 86.3%. Marginal bone loss was assessed one year after loading by panoramic radiographs. The mean bone loss was 1.3 mm mesially and 1.1 mm distally [23]. In 1999, they increased the sample to 356 implants, obtaining a cumulative success rate of 88.2%, after a mean loading period of 56 months. Of note, most implants (41) failed at stage II surgery before prosthetic loading, and only one implant failed after loading [24]. In 2005, they placed 164 pterygoid implants with titanium oxide surfaces. After 54 months of follow-up, the success rate was statistically significantly higher than in previous studies (96.3%). The authors related this additional 8.1 percentage points gain of implant survival to the change in implant surface from machined to titanium oxide [25]. Vrielinck, et al. [26] placed 14 pterygomaxillary implants and had a success rate

of 71%, after an average follow-up period of 6–24 months. The failures occurred since the implants did not follow the direction of the prepared implant bed and were, therefore, without primary stability. Ridellet al. [27] reported a 100% success rate after placing 22 implants in the maxillary tuberosity area and after a follow-up of 12 years [28].

Bahat performed a study in which he placed 660 implants in 202 patients. The implants were restored with fixed partial metal ceramic or metal restorations, with a follow up period of 12 years after loading. 13 of the implants (2%) failed between placement and loading, 12 implants were lost between loading and the end of the first year, and 10 failed thereafter, two of them as a result of a fracture during the third or fourth year of follow up [29]. In the study of Graves SL, overall survival rate of implant and prosthesis was 96.8% and 99.2%, accordingly [30]. Curi et al. also assessed marginal bone loss around the pterygoid implants after 3 years of follow up, which was found to be 1.21 mm (0.31-1.75 mm), while implant survival rate was 99% and prosthesis survival rate was 97.7% [11]. Finally, Candel et al. reviewed 13 case series and found that the weighted average success of pterygoid implants was 90.7% (range 71%-100%) [22].

In the current study, a 2-year cumulative pterygoid implant success was 96.8%. All four failures occurred within the first two months of immediate loading, indicating that these implants failed to osseointegrate. No late failures were noted during the study follow up period, meaning that the pterygoid implants did not lose osseointegration. Moreover, little bone loss occurred around the pterygoid implants after 24 months of loading (mean 0.28 mm; range 0.17 mm to 0.39 mm), in comparison to the reported ranges in the literature.

Importantly, in the present study the implants were evaluated by both qualitative and quantitative methods, so as to evaluate their success, and not only their survival. Whereas, the former studies have analyzed the conventional pterygoid implants only by means of survival vs. failure. An individual implant in the survival group is defined as an in situ implant, neither meeting success criteria nor being a dropout, while an implant belonging to the success group has been actively tested and found to meet defined criteria. The clinical manifestation of osseointegration is the absence of mobility of the individual implant [31]. The most appropriate way (gold-standard) to prove implant stability is to perform defined clinical testing of each individual implant-abutment unit [21]. However, this is an invasive procedure, and annual removal of the connected prostheses was not clinically and scientifically justified if patients were asymptomatic. In the present study, the clinical stability of each pterygoid implant was evaluated at the time of permanent restoration delivery (up to 7 days after surgery). The absence of mobility and symptoms, like pain and discomfort, were regarded as a reliable sign for no failure, but not the gold-standard, which might

hinder some implants that failed or were nearly to fail asymptotically from being properly diagnosed. Afterwards, implants were assessed by calibrated panoramic radiographs, and marginal bone loss was measured on them. Moreover, patients, who's general health has changed or became uncooperative with the routine dental hygiene or hygienist's visits were excluded from the study analysis. The reason for this exclusion was to assure no impact of general and dental health changes on study data through the entire observational period.

The results of the current study should be interpreted with appropriate caution due to several limitations. First, the patients volunteered to participate in the study. The voluntary response samples are typically more biased than random samples, which are more empirically defensible. Second, the retrospective data used in the study may have great limitations in terms of control and reporting of data accuracy, past practice performance, confounding information, reliability and validity. Thus, the study design might have hidden some information due to its retrospective nature, the limited period of the follow-up and to a lesser extent the limited number of patients. Third, radiographic evaluation was a fundamental part of our study design. While radiographs have been traditionally used for evaluating the implant bone loss, they have limitations in terms of interpretation, calibration, intra-examiner standardization and cross examiner reliability. In order to overcome these limitations as much as possible, we standardized our panoramic radiographs by using the same panoramic machine and software with the same parameters. The radiographs were calibrated and two radiologists were assessing the bone loss consistently by the same method. Moreover, the study analyzed only highly cooperative, healthy patients with no history of sinus bone augmentation or any other bone grafting procedures in the maxilla. This unique cohort did not represent the whole population of candidates for atrophic maxillary reconstruction. Therefore, the current study reflects TTPHIL pterygoid implants success only in patients with specific characteristics.

In order to support or disprove the current findings, a large random prospective study is required to assess the clinical and radiographic success of the TTPHIL pterygoid implants over a longer period of follow-up in both healthy and medically compromised patients. Further studies aimed at evaluating the TTPHIL technique success, should include pterygoid implants placed by highly experienced surgeons, as the implants in the current study were placed by an oral implantologist with over 15 years of experience, which is one of the potential limitations of the TTPHIL technique that the dental surgeon has to be experienced enough with operating in a flapless conditions in the posterior maxilla. Another potential challenge of the TTPHIL technique is incorrect implant angulation or insufficient engagement within the pterygoid bony region due to inaccuracies in the fabrication and/or alignment of the surgical guide or use of implant with inappropriate dimensions.

Additionally, failure of the pterygoid implant might jeopardize the whole rehabilitation or a substantial span of it, due to limited number of implants in the TTPHIL concept.

Of note, the TTPHIL method has many potential benefits in relation to the traditional staged pterygoid implant surgery, particularly during the current COVID-19 pandemic. The COVID-19 pandemic has impacted the accessibility and continuity of dental care, which might jeopardize or prolong the already long rehabilitative sequence of conventionally placed pterygoid implants, as usually several months (6-12 months) elapse from implant insertion to final restoration. During this long timeline, dental care might become unavailable due to quarantines, personal isolation or other pandemic related issues. Very high theoretical risk of COVID-19 transmission in dental settings might also deter patients from completing all visits needed for successful rehabilitation [32]. Various potential challenges of the COVID-19 pandemic can be overcome as implants done by the TTPHIL method are usually rehabilitated within few days. The TTPHIL technique is innovative by providing a minimally invasive way for immediate final rehabilitation even in a severe atrophic maxilla by utilizing computer planned surgery and a surgical guide, which enable flapless, precise and non-complex surgery. General practitioners as well as oral and maxillofacial surgeons may utilize the TTPHIL technique for routine pterygoid implant placement, therefore the present study is clinically relevant to the global dental community.

Conclusions

The current study may suggest evidence for higher success rates and comparable or less bone loss around pterygoid implants placed by TTPHIL® technique in healthy individuals, in comparison to conventional techniques. TTPHIL pterygoid implants also provide stability for the prosthesis within two years of follow-up. TTPHIL technique may be particularly suitable for use during the COVID-19 pandemic due to limited number of required appointments and short period from implantation to final rehabilitation. The short to moderate retrospective follow-up period and the limited number of patients, however, set restrictions to this study and more research is required with longer follow-up period and larger population of patients.

Acknowledgments: The authors thank Dr. Mahesh Khairnar, M.D.S, for his generous assistance in independent reviewing the statistical methodology and study results and for his useful comments. (Assistant Professor, Department of Public Health Dentistry, Bharati Vidyapeeth Dental College and Hospital, Sangli, India)

Competing Interests Disclaimer

Authors have declared that no competing interests exist. The products used for this research are commonly and predominantly

use products in our area of research and country. There is absolutely no conflict of interest between the authors and producers of the products because we do not intend to use these products as an avenue for any litigation but for the advancement of knowledge. Also, the research was not funded by the producing company rather it was funded by personal efforts of the authors.

References

1. Brånemark PI, Adell R, Breine U, Hansson BO, Lindström J, et al. (1969) Intra-osseous anchorage of dental prostheses. I. Experimental studies. *Scand J Plast Reconstr Surg* 3: 81-100.
2. Jinfeng L, Jinsheng D, Xiaohui W, Yanjun W, Ningyu W (2017) The Pneumatization and Adjacent Structure of the Posterior Superior Maxillary Sinus and Its Effect on Nasal Cavity Morphology. *Med Sci Monit* 23: 4166-4174.
3. Ko YC, Huang HL, Shen YW, Cai JY, Fuh LJ, et al. (2017) Variations in crestal cortical bone thickness at dental implant sites in different regions of the jawbone. *Clin Implant Dent Relat Res* 19: 440-446.
4. Kim YH, Choi NR, Kim YD (2017) The factors that influence postoperative stability of the dental implants in posterior edentulous maxilla. *Maxillofac Plast Reconstr Surg* 39: 2.
5. Ali SA, Karthigeyan S, Deivanai M, Kumar A (2014) Implant rehabilitation for atrophic maxilla: a review. *J Indian Prosthodont Soc* 14: 196-207.
6. Parra M, Olate S, Cantín M (2017) Clinical and biological analysis in graftless maxillary sinus lift. *J Korean Assoc Oral Maxillofac Surg* 43: 214-220.
7. Rodríguez X, Lucas-Taulé E, Elnayef B, et al. (2016) Anatomical and radiological approach to pterygoid implants: a cross-sectional study of 202 cone beam computed tomography examinations. *Int J Oral Maxillofac Surg* 45: 636-640.
8. Butterworth CJ, Rogers SN (2017) The zygomatic implant perforated (ZIP) flap: a new technique for combined surgical reconstruction and rapid fixed dental rehabilitation following low-level maxillectomy. *Int J Implant Dent* 3: 37.
9. Cara-Fuentes M, Machuca-Ariza J, Ruiz-Martos A, Ramos-Robles MC, Martínez-Lara I (2016) Long-term outcome of dental implants after maxillary augmentation with and without bone grafting. *Med Oral Patol Oral Cir Bucal* 21: e229-235.
10. Pabst AM, Walter C, Ehbauer S, et al. (2015) Analysis of implant-failure predictors in the posterior maxilla: a retrospective study of 1395 implants. *J Craniomaxillofac Surg* 43: 414-420.
11. Curi MM, Cardoso CL, Ribeiro KeC (2015) Retrospective study of pterygoid implants in the atrophic posterior maxilla: implant and prosthesis survival rates up to 3 years. *Int J Oral Maxillofac Implants* 30: 378-383.
12. Langer B, Langer L, Herrmann I, Jorneus L (1993) The wide fixture: a solution for special bone situations and a rescue for the compromised implant. Part 1. *Int J Oral Maxillofac Implants* 8: 400-408.
13. Tinsley D, Watson CJ, Preston AJ (2002) Implant complications and failures: the fixed prosthesis. *Dent Update*. 29: 456-460.
14. Aglietta M, Siciliano VI, Zwahlen M, et al. (2009) A systematic review of the survival and complication rates of implant supported fixed dental prostheses with cantilever extensions after an observation period of at least 5 years. *Clin Oral Implants Res* 20: 441-451.

15. Tulasne JF (1992) Osseointegrated fixtures in the pterygoid region. In: Worthington P, Branemark PI, eds. *Advanced Osseointegration Surgery. Applications in the Maxillofacial Region*. Chicago, Quintessence Publishing Co. Ltd 1992:182-188
16. Venkat Nag P, Sarika P, Pavankumar A (2017) TTPHIL-ALL TILT™ Concept - An innovative technique in immediate functional loading implant placement in maxilla. *Scholars Journal of Dental Sciences* 4: 397-399.
17. Venkat Nag P, Sarika P, Khan R, Bhagwatkar T (2018) Immediate implantation and loading in just two days with TTPHIL technique using CAD/CAM prosthesis. *International Journal of Applied Dental Sciences* 4: 209-213.
18. Venkat Nag P, Sarika P, Khan R, Bhagwatkar T (2018) Tall and tiled pin hole immediately loaded implants (TTPHIL) technique for maxillary arch rehabilitation. *International Journal of Applied Dental Sciences* 5: 104-110.
19. Nag PVR, Dhara V, Puppala S, Bhagwatkar T (2019) Treatment of the Complete Edentulous Atrophic Maxilla: The Tall Tilted Pin Hole Placement Immediate Loading (TTPHIL)-ALL TILT™ Implant Option. *J Contemp Dent Pract* 20: 754-763.
20. Albrektsson T, Zarb G, Worthington P, Eriksson AR (1986) The long-term efficacy of currently used dental implants: a review and proposed criteria of success. *Int J Oral Maxillofac Implants* 1: 11-25.
21. Roos J, Sennerby L, Lekholm U, Jemt T, Gröndahl K, et al. (1997) A qualitative and quantitative method for evaluating implant success: a 5-year retrospective analysis of the Brånemark implant. *Int J Oral Maxillofac Implants* 12: 504-514.
22. Candel E, Peñarrocha D, Peñarrocha M (2012) Rehabilitation of the atrophic posterior maxilla with pterygoid implants: a review. *J Oral Implantol* 38: 461-466.
23. Balshi TJ, Lee HY, Hernandez RE (1995) The use of pterygomaxillary implants in the partially edentulous patient: a preliminary report. *Int J Oral Maxillofac Implants* 10: 89-98.
24. Balshi TJ, Wolfinger GJ, Balshi SF (1999) Analysis of 356 pterygomaxillary implants in edentulous arches for fixed prosthesis anchorage. *Int J Oral Maxillofac Implants* 14: 398-406.
25. Balshi SF, Wolfinger GJ, Balshi TJ (2005) Analysis of 164 titanium oxide-surface implants in completely edentulous arches for fixed prosthesis anchorage using the pterygomaxillary region. *Int J Oral Maxillofac Implants* 20: 946-952.
26. Vrielinck L, Politis C, Schepers S, Pauwels M, Naert I (2003) Image-based planning and clinical validation of zygoma and pterygoid implant placement in patients with severe bone atrophy using customized drill guides. Preliminary results from a prospective clinical follow-up study. *Int J Oral Maxillofac Surg* 32: 7-14.
27. Ridell A, Gröndahl K, Sennerby L (2009) Placement of Brånemark implants in the maxillary tuber region: anatomical considerations, surgical technique and long-term results. *Clin Oral Implants Res* 20: 94-98.
28. Ardekian L, Levit L, Ishabaiv R, Levit M (2018) Pterygoid dental implants: an alternative solution for treatment of posterior atrophic maxilla. Clinical report on a series of 20 patients. *World Journal of Oral and Maxillofacial Surgery* 1: 1007.
29. Bahat O (2000) Brånemark system implants in the posterior maxilla: clinical study of 660 implants followed for 5 to 12 years. *Int J Oral Maxillofac Implants* 15: 646-653.
30. Graves SL (1994) The pterygoid plate implant: a solution for restoring the posterior maxilla. *Int J Periodontics Restorative Dent* 14: 512-523.
31. Albrektsson T, Isidor F (1994) Consensus report of session IV. In: Land NP, Karing T, eds. *Proceedings of the First European Workshop on Periodontology*. London, Quintessence Publishing Co. Ltd; 1994: 365-369
32. Levit, M.; Levit L (2021) Infection risk of COVID-19 in dentistry remains unknown. A preliminary systematic review. *Infect Dis Clin Pract* 29: e70-e77.